Indian J Lepr 2015, 87 : 165-168
© Hind Kusht Nivaran Sangh, New Delhi
http://www.ijl.org.in

Case Report

Ileofemoral Deep Vein Thrombosis (DVT) in Steroid Treated Lepra Type 2 Reaction Patient

P Thangaraju[1], VC Giri[1], U Aravindan[1], V Sajitha[2] and MK Showkath Ali[1]

Received : 29.03.2015 Revised : 10.09.2015 Accepted : 23.09.2015

In 1998 a 57-year-old man having skin leisons of 6 months duration reported to Central Leprosy Teaching and Research Institute (CLTRI), Chengalpattu. It was diagnosed as a case of borderline lepromatous leprosy with a type 2 lepra reaction, was treated with multi bacillary-multi drug therapy (MBMDT) for a period of12 months and the patient was released from treatment (RFT) in September 1999. For reactions the patient was treated with prednisolone for more than 10 months. After 14 years in April 2013 the same patient presented to CLTRI with complaints of weakness of both hands with loss of sensation for 4 months, so making a diagnosis suggestive of MB relapse with neuritis the patient was started with MB-MDT for period of 12 months with initial prednisolone 25 mg OD dose then increased to 40 mg for painful swollen leg and to follow the neuritis associated pain and swelling. Increased dose is not beneficial and the patient was investigated for other pathology. Doppler ultra-sound revealed a left ileofemoral deep vein thrombosis (DVT) in that patient with levels. Prednisolone was withdrawn and the patient was started with anticoagulant heparin followed by warfarin. During this period rifampicin was also withdrawn. After patient was in good condition he was put on MB-MDT regimen. Till the 6th pulse the patient continues to show improvement in functions without steroids and any tenderness, he is taking multivitamins; regular physiotherapy. This DVT appears to be due to prednisolone and such causative relationship though rare should be kept in mind when patient on long term treatment with steroids/ and or immobilized or on prolonged bed rest report with such symptomatology.

Keywords : Lepra reaction, Steroid, Deep vein thrombosis

Introduction

Erythema Nodosum leprosum (ENL) is an immune-mediated reaction in lepromatous (LL) and borderline lepromatous (BL) type of leprosy. The clinical presentation in ENL patients may vary from a very painful erythema ornodules which appear on the trunk, both extremities and in face. It is associated with generalized symptoms of fever, arthritis, myositis, lymphadenitis, iridocyclitis and painful neuritis (Teo et al 2002).

[1] P Thangaraju, MD, PGD (Diab), Medical Officer
[1] VC Giri, MD (PSM) Assistant Director (Epidemiology)
[1] U Aravindan, M.Sc, Junior Statistical Officer
[2] V Sajitha, MBBS, Junior Resident(Paediatrics)
[1] MK Showkath Ali, DPH, FMTP, Director
Central Leprosy and Teaching Research Institute, Ministry of Health and Family Welfare, Govt of India, Chengalpattu
[2] Karpaga Vinayaga Institute of Medical Sciences, Tamilnadu
Correspondence to: P Thangaraju **Email:** drpugal23@gmail.com

These type-2lepra reaction occur in 30-50% of Lepromatous type and around 10% of Borderline lepromatous leprosy. Bacteriological Index (BI) higher than 4+ carries the risk of complications (Pocaterra et al 2006). The most common drugs used for treating ENL are corticosteroids (Prednisolone), clofazimine and Thalidomide. Various immune suppressants like cyclosporine A (CyA), azathioprine, pentoxifylline, myco-phenolate mofetil, methotrexate and intravenous immunoglobulin G were also tried but with least benefits (Scollard et al 2006).

Case Report

Central Leprosy Teaching and Research Institute (CLTRI), Chengalpattu, is an apex training and research institute having tertiary leprosy patient care facility. A 57-year-old man reported to CLTRI in 1998 for skin lesions of 6 months duration. The lesions were coppery patches distributed in the entire back sparing midline and both the upperand lower limbs with definite loss of sensation (Fig 1a). Peripheral and cutaneous nerves like ulnar, radial cutaneous and lateral popliteal were thickened and tender, bilateral involvement was seen. Staining by Ziehl-Neelsen method also demonstrated small numbers of acid-alcohol-fast bacilli, arranged singly and in clumps (Fig 1b). The slit skin smear was positive (bacteriological index 2+ and morphological index of 40%), and electromyography showed a mild to moderate sensory-predominant axonal polyneuropathy. It was diagnosed as a case of borderline lepromatous leprosy with a type-2 lepra reaction and was treated with MB-MDT comprising rifampicin 600mg/d, clofazimine 300mg/d and dapsone 100mg/d on the first day of the month fully supervised, and dapsone 100mg/d and clofazimine 50 mg/d daily self administered for 12 months and the patient was released from treatment in September 1999. For reactions the patient was started on prednisolone with a dose of 60 mg/d. The patient was on prednisolone till the mid of 1999 and standard tapering of doses was done with improvements in symptoms and stopped when the lepra reactions subsided. After 14 years in April 2013 the same patient presented to CLTRI with complaints of weakness with loss of sensation of both hands

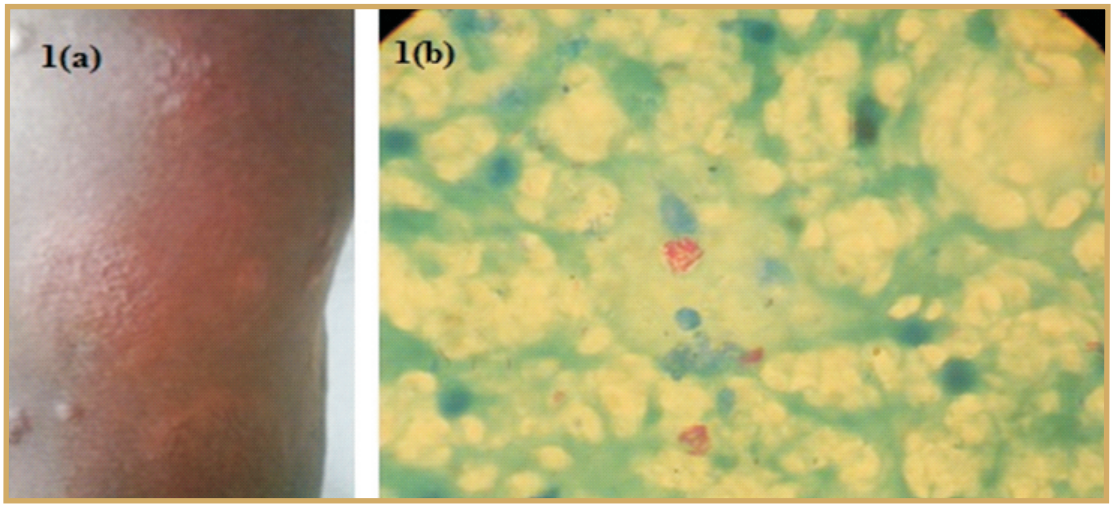

Fig 1 : (a) Coppery patches in the back of the arm (diagnosed Lepromatous Leprosy).
(b) Acid Fast Bacilli in the Smear from the lesion site (Multi Bacillary).

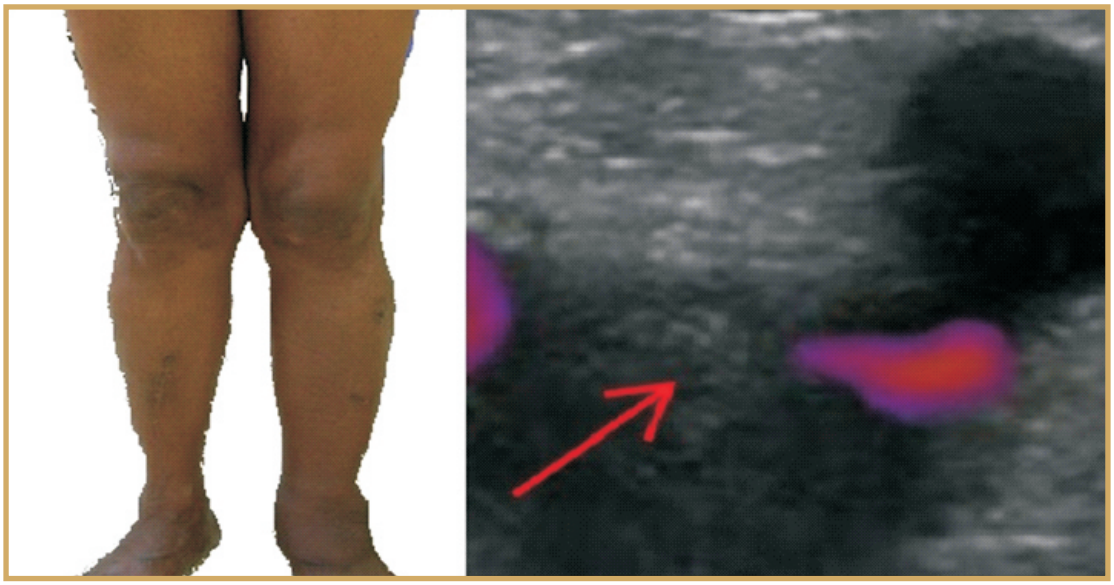

Fig 2 : (a) Symptomatic patient with swollen Left Lower Limb.
(b) Dupplex image showing the Thrombus in the Left Femoral Vein (arrow head)

Table 1 : Various Parameters with Their Reference Values

Parameters	Values	Normal range
Immunoglobulin (Ig) A		
anti-2-glycoprotein I antibodies (anti-2GPI)	31.0 U	< 20 U
IgG antiphosphatidylserine antibodies	43.6 U	< 16.0 U
IgG phospholipid units (GPL) /ml	29.60	25.00 GPL/ml

and in lower limbs there was a loss of sensation on both side below the lower one third of leg upto toe for 4 months. The patient was ambulatory but was walking with difficulty. On examination, patient was found to have bilateral minimal claw hand deformity with a diminished grip of both hands with bilateral ulnar neuritis with loss of sensation of both hands. Both ankles and feet show anaesthesia with evidence of neuritis of both lateral popliteal nerves. After making a diagnosis suggestive of MB relapse with neuritis the patient was started with MB-MDT for 12 months with prednisolone 25 mg OD dose. During the course of 4th pulse the patient presented with left swollen painful leg (Fig 2a) and steroid dose was increased to 40 mg OD for a week to follow the neuritis associated pain and swelling. Since the pain didn't respond to increased dose of prednisolone he was referred to nearest tertiary hospital for further evaluation. Doppler ultra-sound revealed a left ileofemoral deep vein thrombosis (Fig 2b).

The laboratory reports were all normal except for a slight elevation in antiphospholipid antibody levels (Table 1).

Prednisolone was withdrawn and the patient was started with anticoagulant heparin followed by warfarin. LMW heparin was given in a dose of

1 mg/kg subcutaneous bid for 5 days followed by 10 mg oral warfarin for initial 2 days and thereafter 5mg for 8 weeks. Care has been taken for avoiding rifampicin. The tests were repeated after 8 weeks and the results were within normal range. The patient was received back in CLTRI in good general condition for remaining MB-MDT regimen. Now the patient is on the 6th pulse without steroids and any tenderness, taking multivitamins. The patient is regularly doing his physiotherapy and finds himself with the improvement in functions.

Discussion

Sheskin (1965) first reported the usefulness of thalidomide in the treatment of type-2 lepra reactions and its efficacy is around 68–91% has since been confirmed in multiple clinical studies (Iyer et al 1971) attributed to its inhibitory actions on tumour necrosis factor (TNF)-α. The elevated TNF-α level showed a decrease in levels with thalidomide treatment (Deng et al 2003). One of the adverse effects of thalidomide is venous thromboembolism (VTE) when particularly combined with systemic corticosteroids. Among the drugs glucocorticoids are commonly thought to be a procoagulantncreasing the risk of thromboembolic complications (Wadman and Werner 1972). Some studies have reported DVT in patients of ENL treated with a combination of both steroids and thalidomide (Vetrichevvel et al 2008). This is the first case report where DVT appears to have occurred primarily due to prednisolone alone taken in high dose for a long time. Since the patient was not confined to bed and mobile, the only possible cause is the drug prednisone, which is a known to increase procoagulant factors as documented by Wadman and Werner (1972). The patient developed signs and symptoms only after the start of steroid which he took for 4 months. There is also a risk in patient as he was previously exposed to high dose of steroid in the beginning of treatment in 1998. Another significant clinical implication of this case report is that, painful leg generally makes us to think about the neuritis in reaction cases. Prima facie DVT in this case appears to be due to prednisolone and such causative relationship though rare should be kept in mind when patient on long term treatment with steroids/ and or are immobilized or on prolonged bed rest report with such symptomatology. In such cases it would be advisable to investigate the vascular involvement in addition to the neuritis.

References

1. Deng L, Ding W and Granstein RD (2003). Thalidomide inhibits tumor necrosis factor-alpha production and antigen presentation by Langerhans cells. *J Invest Dermatol*. **121**: 1060-1065.
2. Iyer CGS, Languillon J, Ramanujam K et al (1971). WHO co-ordinated short-term double-blind trial with thalidomide in the treatment of acute lepra reactions in male lepromatous patients. *Bull World Health Organ*. **45**: 719-732.
3. Pocaterra L, Jain S, Reddy R et al (2006). Clinical course of erythema nodosum leprosum: an 11-year cohort study in Hyderabad. *India Am J Trop Med Hyg*. **74**: 868-879.
4. Scollard DM, Adams LB, Gillis TP et al (2006). The continuing challenges of leprosy. *Clin Microbiol Rev*. **19**: 338-381.
5. Sheskin J (1965). Thalidomide in the treatment of lepra reactions. *Clin Pharmacol Ther*. **6**: 303-306.
6. Teo SK, Resztak KE, Scheffier MA et al (2002). Thalidomide in the treatment of leprosy. *Microbes Infect*. **4**: 1193-1202.
7. Vetrichevvel TP, Pise GA and Thappa DM (2008). Case report of venous thrombosis in a leprosy patient treated with corticosteroid and thalidomide. *Lepr Rev*. **79**: 193-195.
8. Wadman B and Werner I (1972). Thromboembolic complications during corticosteroid treatment of temporal arthritis. *The Lancet*. **1**: 907.

How to cite this article : Thangaraju P, Giri VC, Aravindan U et al (2015). Ileofemoral Deep Vein Thrombosis (DVT) in Steroid Treated Lepra Type 2 Reaction Patient. *Indian J Lepr.* **87** : 165-168.